



Ketoconazole Shampoo: Effect of Long-Term Use in Androgenic Alopecia

Deze studie gaat over het effect van het langdurig gebruik van ketoconazol shampoo in de strijd tegen androgene alopecia. De hieraan gerelateerde haargroeiproducten zijn:

- [Regenepure DR shampoo](#)

C. Piérard-Franchimont^a
 P. De Doncker^b
 G. Cauwenbergh^c
 G.E. Piérard^a

^a Department of Dermatopathology,
 University of Liège, and

^b Janssen Research Foundation, Beerse, Belgium;

^c Johnson and Johnson Research and
 Development, Skillman, N.J., USA

Ketoconazole Shampoo: Effect of Long-Term Use in Androgenic Alopecia

Key Words

Androgenic alopecia
 Ketoconazole
 Minoxidil
Malassezia spp.

Abstract

Background: The pathogenesis of androgenic alopecia is not fully understood. A microbial-driven inflammatory reaction abutting on the hair follicles might participate in the hair status anomaly. **Objective:** The aim of our study was to determine if ketoconazole (KCZ) which is active against the scalp microflora and shows some intrinsic anti-inflammatory activity might improve alopecia. **Method:** The effect of 2% KCZ shampoo was compared to that of an unmedicated shampoo used in combination with or without 2% minoxidil therapy. **Results:** Hair density and size and proportion of anagen follicles were improved almost similarly by both KCZ and minoxidil regimens. The sebum casual level appeared to be decreased by KCZ. **Conclusion:** Comparative data suggest that there may be a significant action of KCZ upon the course of androgenic alopecia and that *Malassezia* spp. may play a role in the inflammatory reaction. The clinical significance of the results awaits further controlled study in a larger group of subjects.

Introduction

The pathobiology of androgenic alopecia (AGA) is uncertain. The genetic predisposition and the influence of androgens is beyond doubt. However, these factors do not explain the presence of a substantial lymphoid infiltrate abutting on the infrainfundibulum and isthmus of transitional hair follicles [1, 2]. Histological observations suggest a putative role of the AGA inflammatory cells on the follicular stem cells [1, 2]. In addition interleukin 1 has been proposed to be a cytokine inducing hair loss [3]. The negative influence of inflammation on AGA hair status is further supported by clinical observations showing AGA exacerbation following intercurrent episodes of other inflammatory dermatoses, particularly seborrheic dermatitis.

Currently, there is near unanimous recognition that ketoconazole (KCZ) is highly effective for treating dandruff and seborrheic dermatitis. Improvement in the skin condition is accompanied by a reduction in *Malassezia* spp. colonization of the skin sur-

face [4–6]. A direct anti-inflammatory effect of KCZ is also part of the mechanisms underlying the efficacy of topical KCZ [7–9]. As the surface of the scalp and the follicular infundibula normally harbor a microflora of the same nature as in seborrheic dermatitis [10, 11], we hypothesized that the inflammation abutting on the AGA hair follicles might also be related to the presence of some members of that microflora [2]. Hence, antimicrobials might reduce inflammation typical of AGA, and, in turn, improve the hair status [2].

In the present study, we tested this hypothesis using KCZ shampoo in AGA and evaluating changes in the hair status.

Materials and Methods

Study 1

A total of 39 men aged between 21 and 33 years who presented with grade III vertex AGA according to the Hamilton-Norwood classification [12, 13] were included in the study. The duration of alopecia ranged from 2

to 6 years. None had presented dandruff or seborrheic dermatitis in the previous 6 months. Twenty-seven subjects used exclusively 2% KCZ shampoo (Nizoral® shampoo, Janssen Pharmaceutica) 2–4 times weekly over a 21-month period. Twelve other subjects used the unmedicated Wash and Go® shampoo (Vidal Sassoon) in a similar way. Controls included 22 age-matched men who had no family history of AGA and who were unaware of changes in hair quality, density or shedding. They did not complain of dandruff and seborrheic dermatitis. Half of them received the KCZ shampoo and the other half the nonmedicated shampoo. The products were used ad libitum. No AGA and nonalopecic subjects had applied products known to influence hair growth either before or during the study.

Hair samples were obtained from the vertex area at inclusion and every trimester during the 21-month study period. Precise relocation of the sample site was achieved by employing a 3-point midline and facial coordinates. Trichograms yielded the proportion of hairs in anagen phase (A, %). Computer-

KARGER

Fax +41 61 306 12 34
 E-Mail karger@karger.ch
 www.karger.com

© 1998 S. Karger AG, Basel
 1018–8665/98/1964–0474\$15.00/0

This article is also accessible online at
<http://BioMedNet.com/karger>

Prof. G.E. Piérard, MD, PhD
 Department of Dermatopathology
 CHU Sart-Tilman
 B–4000 Liège (Belgium)
 Tel. +32 4 366 24 08, Fax +32 4 366 29 76

ized image analysis (MOP Videoplan Kontron, Eching, Germany) was applied to the same samples to derive the average diameter (D , μm) of the hair shafts at 1.5 cm from the bulb. Both hair variables employed are known to decrease during AGA progression. Hence, an AGA pilary index (PI) was derived to combine these variables following $\text{PI} = A \times D$.

Seborrhea is often present in AGA [14] and fuels growth of lipophilic microorganisms. It is therefore not desirable for both biological and cosmetic reasons. The sebum casual level at the skin surface was measured at each evaluation time using the Sebumeter® (Courage and Khazaka, Cologne, Germany). Four measurements were taken at random on the alopecic vertex and the average was calculated. There was a treatment-free interval of at least 36 h between the last shampoo and sebumetric measurements.

Study 2

In light of the data yielded by the first study, a comparison was made between effects of KCZ and minoxidil on the AGA hair status. Two groups of 4 men, aged between 24 and 29 years, who showed grade III vertex AGA, were selected after giving their informed consent. A 4-mm punch biopsy was taken from the vertex area at inclusion in the study and after a 6-month treatment using either the 2% KCZ shampoo (Nizoral) or the combination of 2% minoxidil lotion (Rogaine®, Upjohn) once daily and the unmedicated shampoo Wash and Go. Shampoos were used ad libitum. Biopsies were formalin-fixed and paraffin-embedded. Step sections were cut parallel to the skin surface. Computerized image analysis (MOP Videoplan Kontron) was applied to the section where the sebaceous glands had the largest relative area. For each pilary unit, both the hair shaft diameter and the sebaceous gland area were recorded.

Statistical Analysis

The distribution of each variable was characterized by the median, 95% confidence interval and mode. When the distribution was normal, the mean (M), standard deviation (SD) and the coefficient of variation ($V = 10^2 \text{SD} \cdot M^{-1}$) were calculated. Group differences at entry in the study were compared statistically employing the Mann-Whitney U test for unpaired samples. Variance (ANOVA) and regression model analyses were applied to determine the relationship between variables. All results were considered to be significant at the 5% critical level.

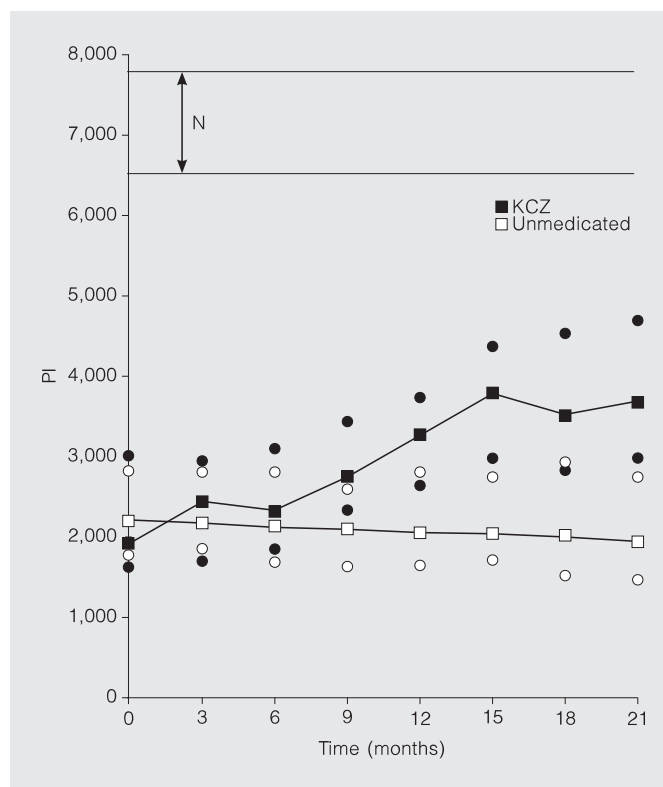


Fig. 1. Variations in time of the PI (median and 95% confidence interval) in subjects with AGA. The use of 2% KCZ shampoo (■) is associated with a significant increase in PI, while the natural evolution of the alopecia on unmedicated shampoo (□) shows a slow progressive decrease in PI. ○, ● = 95% confidence intervals. Values in non-alopecic subjects (N) are presented by the 10th and 90th percentile boundaries.

Results

Study 1

At entry in the study, subjects with AGA had a significantly lower PI ($p < 0.001$) than controls (fig. 1). No significant difference was then found between PI of the two AGA subgroups. In control subjects without AGA, the PI remained unchanged during the study, whether they used the KCZ or the unmedicated shampoo. The PI of AGA subjects using the unmedicated shampoo showed a slow linear ($r = 0.56$, $p < 0.05$) decrease in time (fig. 1). Large interindividual differences were evidenced in the AGA evolution as evaluated by the PI. In contrast to such a disease progression, the KCZ group yielded a progressive PI increase that became evident after a 6-month survey and apparently reached a plateau value after about 15 months (fig. 1). However, the overall relationship

between KCZ PI and time was best fitted by a linear regression model ($r = 0.69$, $p < 0.01$).

The mean sebum casual level was significantly ($p < 0.05$) higher in AGA subjects ($115 \pm 47 \mu\text{g}/\text{cm}^2$) than in controls ($69 \pm 44 \mu\text{g}/\text{cm}^2$). It did not show any evidence for meaningful variation in AGA and normal volunteers using the unmedicated shampoo. A trend in logarithmic decrease ($r = -0.43$, $p < 0.07$) was found in KCZ-treated AGA subjects, reaching a median reduction of 18% at the completion of the study.

Study 2

At entry into the study, the AGA hair density reached $250 \pm 38/\text{cm}^2$ in the KCZ group and $276 \pm 33/\text{cm}^2$ in the minoxidil + unmedicated shampoo group. No significant difference in both hair shaft diameter and sebaceous gland area was present between the two allocated groups receiving one of the

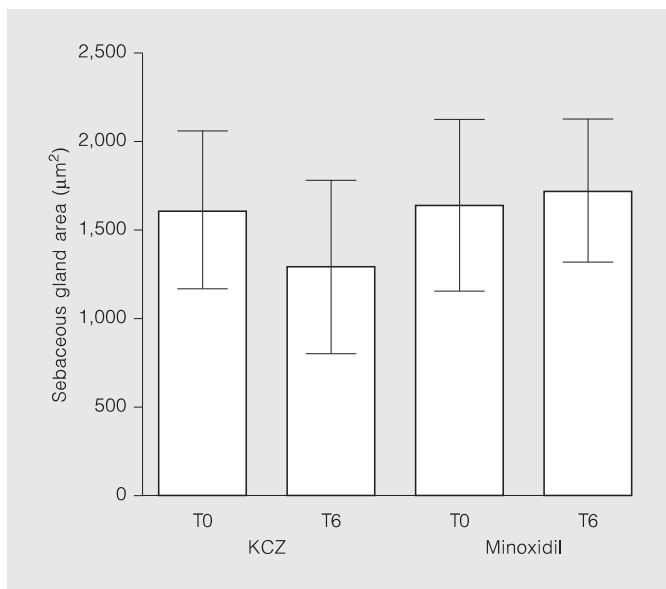
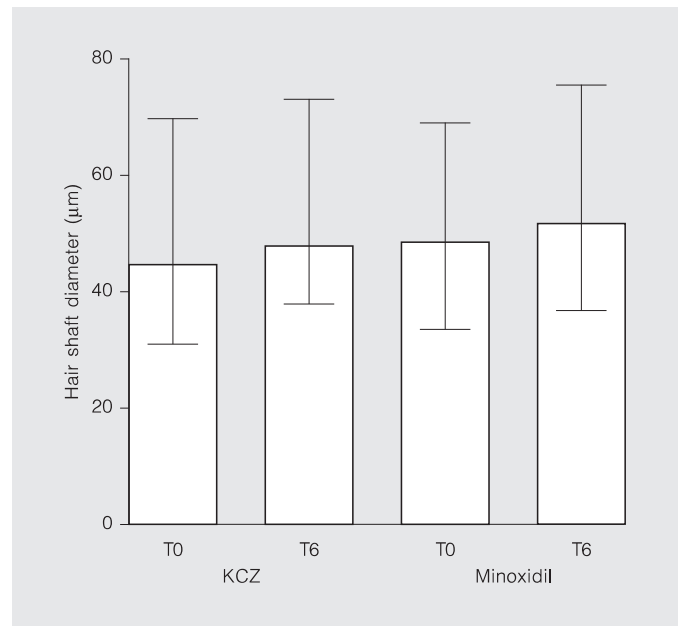
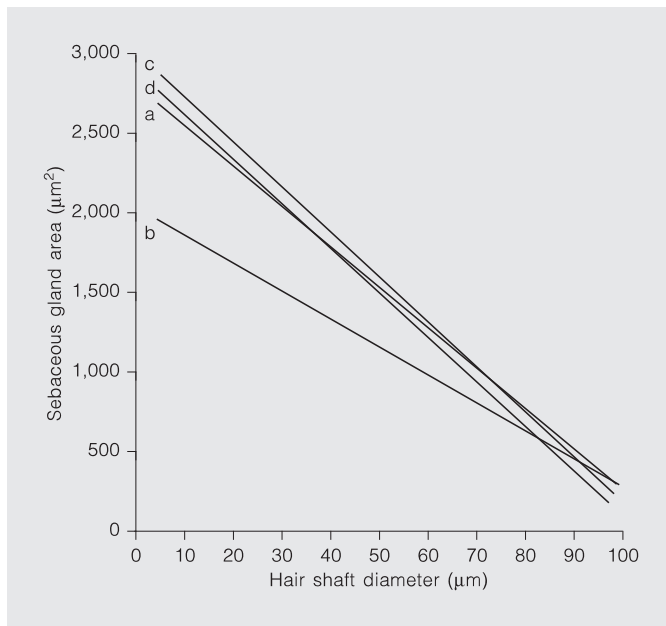


Fig. 2. Negative linear relationships between hair shaft diameter and area of sebaceous glands in AGA. a=Before KCZ treatment (n=126, $r=-0.46$, slope= -0.52 , $p<0.01$); b=after a 6-month KCZ treatment (n=149, $r=-0.42$, slope= -0.39 , $p<0.01$); c=before minoxidil+unmedicated shampoo treatment (n=144, $r=-0.65$, slope= -0.63 , $p<0.01$); d=after a 6-month minoxidil+unmedicated shampoo treatment (n=155, $r=-0.54$, slope= -0.54 , $p<0.01$).

Fig. 3. Median and 95% confidence interval of the hair shaft diameter in AGA: evaluations before (T0) and after a 6-month treatment (T6) using either 2% KCZ shampoo or a combination of minoxidil with an unmedicated shampoo.

Fig. 4. Mean and standard deviation of the sebaceous gland area in AGA: evaluations before (T0) and after a 6-month treatment (T6) using either 2% KCZ shampoo or a combination of minoxidil with an unmedicated shampoo.

two treatments. The median hair shaft diameter was $46.7 \mu\text{m}$ (confidence interval: $29.6-71.8$). The distribution of that hair variable was bimodal in most AGA subjects. The intraindividual coefficients of variation ranged from 32 to 68%. A normal distribution of sebaceous gland area was found with a mean of $1,614 \pm 491 \mu\text{m}^2$. In both subgroups of AGA subjects, a negative linear relationship was found between the hair shaft diameter and the area of the corresponding sebaceous glands (fig. 2).

At completion of the 6-month trial, the hair density reached $296 \pm 22/\text{cm}^2$ (+18%) in the KCZ group and $306 \pm 29/\text{cm}^2$ (+11%) in the minoxidil+unmedicated shampoo group. A 7% increase in the median hair shaft diameter was yielded by both the KCZ shampoo and minoxidil+unmedicated shampoo combination (fig. 3). The bimodal distribution in the values of hair shaft diameter was still present. A 19.4% decrease in the mean sebaceous gland area was observed in the KCZ group (fig. 4). In contrast, the same variable

increased by 5.3% in the minoxidil+unmedicated shampoo group. A negative linear correlation between hair shaft diameter and sebaceous gland area was still present at completion of the study (fig. 2).

Discussion

AGA is the androgenically driven hair loss in genetically predisposed adults. An inflammatory infiltrate rich in immunocompe-

tent T lymphocytes is also present in the balding area [1, 2]. It has been postulated that both hormonal and immunoregulatory mechanisms act synergistically to potentiate follicular injury in AGA [1]. The reason why immunocompetent T cells abut on the external root sheath of transitional AGA hairs remains elusive. However, lipophilic microorganisms harbored in the infundibulum might represent the triggering factor [2]. KCZ was tested in AGA because it is active against *Malassezia* spp. and *Staphylococcus* spp. which are part of the scalp microflora. It also shows some direct anti-inflammatory effect [7–9].

The reduction in 'hair volume' is a notable feature of AGA. It depends on the hair number per unit area, hair diameter and duration of the anagen phase. PI and cross-section analysis of punch biopsies explored these aspects of the hair status. Left untreated, androgen-dependent alopecia progressively deteriorates [15]. This was found in the AGA subgroup using the nonmedicated shampoo

alone. In contrast, both present studies concur to show an unequivocal effect of a 2% KCZ shampoo on hair variables affected by AGA. Hair density and size, and proportion of anagen follicles were all improved. Although the number of subjects was limited in the second study, results obtained with KCZ shampoo compare with minoxidil. It has been stated that medications capable of maintaining the existing hair population should be regarded as effective treatments for AGA [15]. The present data suggest that KCZ should enter this group of drugs. This indication is also supported by the fact that sebumetric analysis and morphometric evaluation of the volume of sebaceous glands indicate a trend in the decrease in sebum production by KCZ. Such a seborregulatory effect of KCZ has previously been suggested [16]. However, a more recent study did not uncover such an aspect but rather indicated an increase in scalp lipid content after a 4-week treatment of seborrheic dermatitis [17]. This finding was ex-

plained by the improvement of sebum delivery onto the skin surface as a result of the elimination of the follicular occlusion. It could also be argued that the squames present at entry of the study served as a reservoir to sebum, thus artificially reducing the measurable sebum flow at the skin surface. In addition, the 4-week treatment phase is, in our experience, too short to reveal any sebo-suppressive activity of KCZ.

In the ultimate analysis, data gained by the two present comparative studies are encouraging. On the basis of the aforementioned observations, we are compelled to conclude that the regular use of a 2% KCZ shampoo may participate to improve the AGA presentation. However, a further controlled study is necessary to confirm the findings in a larger group of patients, both to evaluate the ideal KCZ dosage and formulation, and to fully assess the desirability of routine treatment with topical KCZ in this condition.

References

- 1 Jaworsky C, Kligman AM, Murphy GF: Characterization of inflammatory infiltrates in male pattern alopecia: Implications for pathogenesis. *Br J Dermatol* 1992;127:239–246.
- 2 Piérard GE, Piérard-Franchimont C, Nikkels-Tassoudji N, Nikkels AF, Saint-Léger D: Improvement in the inflammatory aspect of androgenetic alopecia: A pilot study with an antimicrobial lotion. *J Dermatol Treat* 1996;7:153–157.
- 3 Hoffmann R, Happel R: Does interleukin-1 induce hair loss? *Dermatology* 1995;191:273–275.
- 4 Ford GP, Farr PM, Ive FA, Shuster S: The response of seborrheic dermatitis to ketoconazole. *Br J Dermatol* 1984;111:603–607.
- 5 Skinner RB, Noah PW, Taylor RM, Zanolli MD, West S, Guin JD, Rosenberg EW: Double-blind treatment of seborrheic dermatitis with 2% ketoconazole cream. *J Am Acad Dermatol* 1985;12:852–856.
- 6 Piérard GE, Piérard-Franchimont C, Van Cutsem J, Rurangirwa A, Hoppenbrouwers ML, Schrooten P: Ketoconazole 2% emulsion in the treatment of seborrheic dermatitis. *Int J Dermatol* 1991;30:806–809.
- 7 Beetens JR, Loots W, Somers Y, Coene MC, De Clerck F: Ketoconazole inhibits the biosynthesis of leukotrienes in vitro and in vivo. *Biochem Pharmacol* 1986;35:883–891.
- 8 Van Cutsem J, Van Gerven F, Cauwenbergh G, Odds F, Janssen PAJ: The anti-inflammatory effects of ketoconazole. *J Am Acad Dermatol* 1991;25:257–261.
- 9 Yoshimura T, Kudoh K, Aiba S, Tagami H: Anti-inflammatory effects of topical ketoconazole for the inflammation induced on the skin of hairless guinea-pigs by repeated applications of heat-killed spores of *Malassezia furfur*: A comparative study with hydrocortisone 17-butyrate. *J Dermatol Treat* 1995;6:113–116.
- 10 Saint-Léger D, Kligman AM, Stoudemayer TJ: The role of the resident microflora in the pathogenesis of dandruff. *J Soc Cosmet Chem* 1989;40:109–117.
- 11 Piérard-Franchimont C, Arrese JE, Piérard GE: Immunohistochemical aspects of the link between *Malassezia ovalis* and seborrheic dermatitis. *J Eur Acad Dermatol Venereol* 1995;4:14–19.
- 12 Hamilton JB: Patterned loss of hair in man: Types and incidence. *Ann NY Acad Sci* 1951;53:708–728.
- 13 Norwood OT: Male pattern baldness: Classification and incidence. *South Med J* 1975;68:1359–1365.
- 14 Piérard-Franchimont C, Piérard GE: Approche physiopathologique de la séborrhée du cuir chevelu. *Ann Dermatol Vénéréol* 1988;115:451–453.
- 15 Rushton DH, Ramsay ID, Norris MJ, Gilkes JH: Natural progression of male pattern baldness in young men. *Clin Exp Dermatol* 1991;16:188–192.
- 16 Brown M, Evans TW, Poyner T, Tooley PJH: The role of ketoconazole 2% shampoo in the treatment and prophylactic management of dandruff. *J Dermatol Treat* 1990;1:177–179.
- 17 Dobrev H, Zissova L: Effect of ketoconazole 2% shampoo on scalp sebum level in patients with seborrheic dermatitis. *Acta Derm Venereol* 1997;77:132–134.